

野口英世著 Journal of Experimental Medicine 所収論文

この PDF は Journal of Experimental Medicine に掲載された論文を Rockefeller University Press の許可 (2020 年 3 月 18 日付) を得てアップロードしています。

A DEMONSTRATION OF *TREPONEMA PALLIDUM* IN
THE BRAIN IN CASES OF GENERAL PARALYSIS.*

BY HIDEYO NOGUCHI, M.D., AND J. W. MOORE, M.D.

(From the Laboratories of The Rockefeller Institute for Medical Research,
and the Central Islip State Hospital, New York.)

PLATE 50.

In the present communication we wish to report the results of examinations for *Treponema pallidum* on seventy parietic brains. One of us (Noguchi) succeeded in finding the pallidum in twelve out of the seventy specimens.¹

The relationship of paresis to syphilis has, for years, been one of the foremost topics of medical interest, especially to psychiatrists. Since 1857 when attention was first called² to the frequency of syphilis in the history of patients with paresis, the etiological importance of the former disease has steadily gained recognition, until now probably the majority of writers agree with Kraepelin³ that "We can to-day declare with the greatest certainty that syphilitic infection is an essential for the later appearance of paresis." Many, however, including a man of such enormous experience as Nonne, still refuse to concede that syphilis is more than an extremely common causative factor. Nonne⁴ says, "At the outset I desire to make it clear that progressive paralysis is not a specific syphilitic disease of the brain."

Among those who hold "without syphilis, no paresis," there are some who contend that paresis is nothing more nor less than a particular form of tertiary syphilis. Kraepelin objects to this view

* Received for publication, January 11, 1913.

¹ The findings were confirmed later by Dr. Moore as well as by others, among whom we may mention Dr. Flexner and Dr. Dunlap. We take pleasure in expressing our gratitude to Dr. G. A. Smith, Superintendent of the Central Islip State Hospital, for the material studied.

² Esmarch, F., und Jessen, W., *Allg. Ztschr. f. Psychiat.*, 1857, xiv, 20.

³ Kraepelin, E., *Psychiatrie*, Leipzig, 1904, ii.

⁴ Nonne, M., *Syphilis und Nervensystem*, Berlin, 1902.

on two principal grounds,—the distinctly greater interval between syphilitic infection and paresis as compared with that in cerebral syphilis and the refractoriness of paresis to antisyphilitic treatment. This author, however, in commenting on the hitherto vain attempts to find *Treponema pallidum* in the tissues and body fluids of paresis, remarks, “This does not mean that the spirochæta is never present in the body of the paretic. It may have assumed forms so far unknown to us or have located in places where it has not yet been sought or where it is hard to find.”

Of late years a few cases have been reported in which the findings of paresis occurred along with those of cerebral syphilis. Sträussler⁵ has recently added two cases of this combination to several he had already reported. Ranke⁶ and others have demonstrated *Spirochæta pallida* in the pia and vessel sheaths in congenitally syphilitic brains. In this country Dunlap, of the New York State Psychiatric Institute, has also shown the organisms in a case of cerebral syphilis. Dunlap has long been of the opinion that, although tertiary syphilis of the brain and general paralysis are quite distinct and seldom, if ever, occur together, they are but different manifestations of the same process.

The failure up to the present time to discover *Treponema pallidum* in the affected nervous system has doubtless added to the general conception that paresis, although of syphilitic origin, can exist without the pallidum playing an active part in the progressive processes. This assumption is valid, of course, only when we grant that *Treponema pallidum* can infallibly be demonstrated by the microscopical techniques hitherto employed. But, as will be seen presently, this is far from being the case. Besides, the individual experience on the part of the examiner has much to do with whether the organisms are viewed or remain undetected, especially in a tissue in which so many tortuous fibers are present as in the brain.

These facts, coupled with the very significant serological similarities between syphilis and paresis, and the fact that the trypanosome

⁵ Sträussler, *Ztschr. f. d. ges. Neurol. u. Psychiat., Orig.*, 1912, xii, 365.

⁶ Ranke, *Ztschr. f. d. Erforsch. u. Behandl. d. jugendl. Schwachsinn.*, 1909, ii, 32, 81, 211.

can be found in the brain in sleeping-sickness,—a disease in many respects similar to paresis,—led the writers to believe that further search for the syphilitic organism, either in granular or in spirochætal form,⁷ in paresis was warranted. To this end, tissues were taken from seventy parietic brains in the possession of the pathological service of the Central Islip State Hospital and stained with the Levaditi silver method modified in certain respects to produce an elective stain for the pallidum. The specimens in most of the cases were taken from the first right frontal gyrus; in some, from the left hemisphere or gyrus rectus.

The syphilitic organisms were found in twelve cases which were examples of undoubted general paralysis. The cases in which the pallida were found showed the classical physical signs. The post-mortem findings in the brain in every case were definitely those of general paralysis. Ten were men and two were women. Seven were of the cerebral type, and five of the tabetic. In several instances the patients had been picked up on the street in a confused state and had no idea of the duration of the condition. In the seven cases in which the onset could be satisfactorily determined, the average duration was seventeen months, the longest thirty months, and the shortest five months. The majority were much below the average duration, as estimated by various authors, which varies from twenty-four to thirty-two months. It is possible, then, that we are more apt to find the spirochæta in those cases which run a fairly rapid course. The age varied from thirty-three to sixty years, with an average of forty-four years. Brief abstracts of the case records follow.

J. C. (103), age fifty years; duration of disease unknown. He was committed from the workhouse. There was much confusion; he was disoriented and his memory was extremely poor. The knee-jerks were unequal and exaggerated; the pupils sluggish and unequal. His speech was distorted, and there were marked tremors. Convulsions occurred. Death occurred after seven months in the hospital.

C. M. (106), age thirty-nine years; duration unknown, but probably about four months. Syphilis ten years previously. When he was admitted he was depressed and apprehensive; he had hallucinations of hearing; he was disoriented, and his memory was very poor, with spells of marked confusion. The

⁷ Noguchi, H., *Jour. Am. Med. Assn.*, 1912, lix, 1236.

knee-jerks were normal, the pupils sluggish. There were ataxia, distorted speech, coarse tremors, and convulsions. He died after eleven months in the hospital.

F. B. (113), age thirty-six years; duration before admission, fourteen months. Syphilis was denied. On admission he was dull, silly, mildly restless, and had occasional hallucinations. His memory showed marked discrepancies. The knee-jerks were absent, and the pupils slow to light and unequal. His speech was distorted, and he had convulsions. Later he developed a silly elation and deteriorated progressively. Death occurred after fourteen months in the hospital. The total duration of the disease was thirty months.

S. V. (131), colored, age thirty-seven years; the duration of the disease before admission is unknown. Syphilis eight years previously. He was euphoric, his memory was very poor, and he was disoriented. The knee-jerks were much diminished, the pupils slightly slow, his speech ataxic, and there were coarse tremors. Later he developed typical expansive ideas and became very ataxic. Death occurred after twenty-seven months in the hospital.

J. D. (138), age thirty-three years; duration before admission, five months. He was admitted in an hallucinatory depression with nihilistic ideas and a history of a probable attempt at suicide. A complete mental status was impossible. The knee-jerks were exaggerated; pupils unequal, Argyll-Robertson sign present; there were marked tremors. The spinal fluid showed marked lymphocytosis. Death occurred after ten months in the hospital.

F. M. (169), age fifty-five years; duration of disease unknown. He was picked up on the street in a confused condition. He had absurd hypochondriacal ideas; "his insides were falling out," etc. He was disoriented and his memory was very poor. The knee-jerks were exaggerated, and the pupils sluggish. There were marked tremors, unsteadiness, and Romberg's sign. His speech was not seriously affected. Depression continued, and he insisted that he could not breathe or urinate, and that parts of him were dead. He died after four months in the hospital. The spinal fluid showed positive lymphocytosis and a positive Wassermann-Noguchi reaction.

E. W. (170), age forty-four years; duration unknown. He had had syphilis. The psychosis was a simple deterioration with marked confusion and disorientation but no delusions. He was silly, his memory was poor, and there were occasional attacks of excitement. The knee-jerks were diminished, and the pupils slightly slow. The speech showed extreme ataxia. Romberg's sign was present, and tremors were prominent. There were frequent convulsions. Death occurred after two months in the hospital.

E. R. (230), age forty-eight years; duration unknown. When admitted she was much demented, confused, completely disoriented, and her memory was poor. Her mood was one of silly elation. The knee-jerks were exaggerated, the pupillary reaction slow and of narrow range. There was marked distortion of speech and writing. There were coarse tremors and increasing ataxia. The spinal fluid showed marked pleocytosis. Death occurred after six months in the hospital.

M. M. (235), age forty-two years; duration uncertain. She had been blind from optic atrophy for two years before admission and had experienced occasional visual hallucinations, but definite mental symptoms seem to have begun only a few weeks before commitment, when she began to show a change of disposition and became forgetful. Syphilis probably occurred twenty years previously. Her husband was a parietic. On admission she was excited, resisting, and obscene. She seemed clear and gave correct answers in the orientation test but her memory showed marked discrepancies in time relations. The knee-jerks were absent, the pupils rigid, her speech drawing and distorted, no tremors, and only slight ataxia. The spinal fluid showed extreme lymphocytosis. She quieted down, and during the next two years showed a gradual deterioration without any particular mental trend. Ataxia increased steadily; she had occasional apoplectic attacks and convulsions. Death occurred after two years in the hospital.

G. F. (236), age sixty years; duration before admission, one month. He became gradually childish, forgetful, and irritable. When admitted he was disoriented, and his memory was poor. The knee-jerks were absent, and the pupils unequal and slow; his speech was slurring and distorted. There were marked tremors and Romberg's sign. He deteriorated rapidly and died after four months in the hospital.

M. D. (242), age thirty-seven years; duration eight months. The onset seemed to date from an injury to the head. There was a probable history of syphilis. He was depressed, confused, and had attempted suicide. His memory was poor, and he was much demented. The knee-jerks were exaggerated; and the pupils unequal and Argyll-Robertson sign present; his speech was ataxic. There were tremors and occasional convulsions. He died after four months in the hospital. The total duration of the disease was one year.

F. B. (299) (figure 1), age fifty-eight years; duration before admission, one month. There was a probable history of syphilis. He was depressed and whining, and had typical parietic ideas, such as that his bowels never moved, and that he had an incurable disease. He would point to a leg or an arm and say, "See, it's all dead, all gone,—there's no hope." His orientation and memory showed marked defects. The knee-jerks were slightly exaggerated, the pupils slow, his speech was distorted, and tremors were excessive. The spinal fluid showed pronounced lymphocytosis and a positive Wassermann-Noguchi reaction. Death occurred after eleven months in the hospital.

Naturally the first question that arises is, Are these not cases of cerebral syphilis in the narrower sense? In reply to this we can but review briefly the differential points. They all showed, in their clinical course, a diffuse, progressive deterioration in all the mental fields, and not the *démence lacunaire* so often observed in syphilitic brain disease. There were no cranial symptoms or other focal manifestations. These points are admittedly not convincing, for it is possible for an old syphilitic endarteritic-meningitic condition to

simulate paresis so closely as to be indistinguishable by its clinical features from the latter disease. It is upon the post-mortem findings that the diagnosis must depend. Anatomically the brains of our cases showed the usual pial thickening, more marked over the frontal convexity. In two it was also prominent over the gyri recti, cerebellum, and cisterna, but it did not assume the degree of meningitis usually seen in syphilis of the base. In one case (235) there was an old hemorrhagic membrane beneath the dura; in another (131) there was a marked preponderance of the parietic process in the right hemisphere, but these conditions were not represented clinically and the findings were otherwise typical. In the microscopic examination the meningeal process in all cases was diffuse, being more marked in the frontal region. The vessel infiltration was also diffuse and found at all depths of the cortex and in the marrow. Plasma cells were, in each case, numerous and usually outnumbered the lymphocytes. Red cells were always present. The nerve cell alterations and changes in the neuroglia do not present differential characteristics and will not be enumerated. With regard to the vessels, a number of our cases, as in all general paralysis material, showed endarteritic changes. In six there was definite thickening of the vessel walls of the type described as syphilitic. In no instance did the intimal proliferation embarrass the lumen to any extent. In the remaining cases the vessels appeared normal. It seems hardly possible that the presence of the spirochætæ could be traced to the luetic endarteritis, since they were not found associated, at least with those vessels which are visible with the Levaditi stain. In none of the cases were there softenings, and no gummata were found either in gross or microscopically.

The spirochætæ were found in all layers of the cortex with the exception of the outer, or neuroglia layer. One was located at the border of this layer, but not within it. A few were found subcortically. Careful search of the pia failed to reveal any of the organisms. In all instances they seemed to have wandered into the nerve tissue. They were not found in the vessel sheaths and seldom in close proximity to the larger vessels. There seems to be no ratio between the number of spirochætæ and the severity of the

paretic process, although the case in which they were most numerous showed excessive paretic changes.

Whether or not, by improving the technique, *Treponema pallidum* can be demonstrated in a much higher percentage of paretic cases will be determined by further investigations.

EXPLANATION OF PLATE 50.

FIG. 1. *Treponema pallidum* in the cortical layer of the right frontal area of the brain (case 299). Stained, with slight modification, by Levaditi's method. $\times 1,100$.

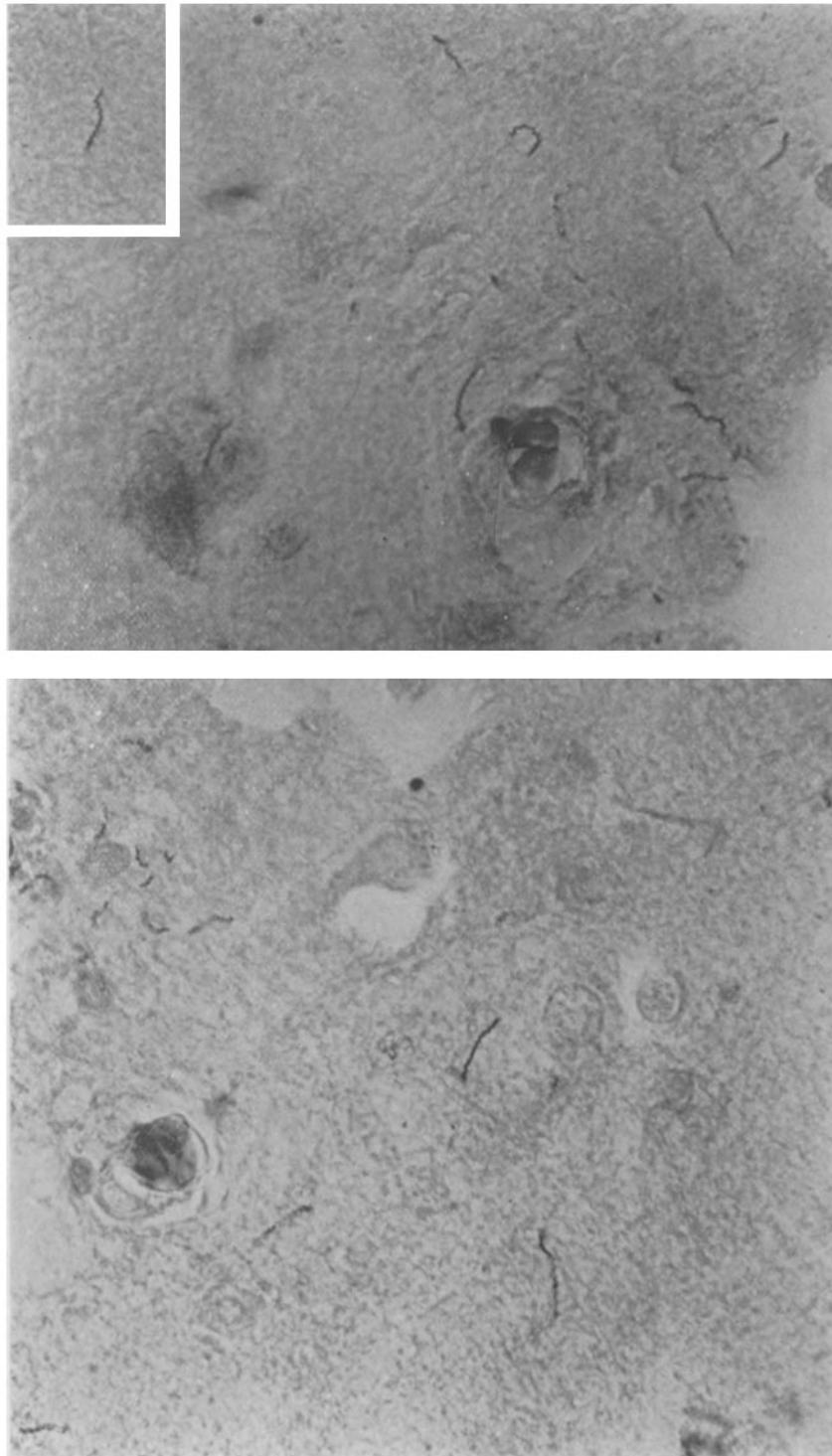


FIG. 1.

(Noguchi and Moore: *Treponema pallidum* in the Brain of General Paralysis.)