

野口英世著 Journal of Experimental Medicine 所収論文

この PDF は Journal of Experimental Medicine に掲載された論文を Rockefeller University Press の許可 (2020 年 3 月 18 日付) を得てアップロードしています。

THE SPIROCHETAL FLORA OF THE NORMAL FEMALE GENITALIA.

BY HIDEYO NOGUCHI, M.D.,¹ AND DAVID J. KALISKI, M.D.

(From the Laboratories of The Rockefeller Institute for Medical Research.)

PLATE 57.

(Received for publication, June 27, 1918.)

The present paper is a sequel to a recently published¹ study of the spirochetal flora of the male genitalia. The subject has been taken up, not because there was any reason for supposing the spirochetal flora of the female genitalia to be different from that of the male, but because of the relative infrequency of any special reference to the former in literature, and in order to obtain more accurate knowledge concerning it. Except for the occurrence of the well known *Spiro-nema refringens* (Schaudinn and Hoffmann²) in both male and female genitalia, practically nothing is known about the spiral organisms in the normal female genitalia.

On anatomic and physiologic grounds the female genitalia undoubtedly afford more favorable conditions for the existence of these saprophytic spirochetes, and the results of examinations of the smegma, films, and washings of the genital mucous membranes of normal adult females conclusively demonstrate that the number of spirochetes of the female is much greater than that of the adult male, although the varieties present appear to be identical in both. As in the male smegma *Treponema calligyrum* is encountered here also as the predominating variety in the majority of specimens, while *Treponema minutum* is present almost constantly but in fewer numbers. On the other hand, the coarse *Spiro-nema refringens* has been less frequently met with here than in the male smegma. The finding may have been accidental but is recorded here for future reference.

¹Noguchi, H., The spirochetal flora of the normal male genitalia, *J. Exp. Med.*, 1918, xxvii, 667.

²Schaudinn, F., and Hoffmann, E., *Arb. k. Gsndtsamte.*, 1905, xxii, 527.

The morphologic and cultural characteristics of these three types were described in a previous publication.¹ In Figs. 1 to 8 *calligyrum*, *minutum*, and *refringens* are easily distinguished. The organisms stained by Fontana's method (Figs. 1 to 3) appear more distinctly than those stained by the mordant gentian violet method (Figs. 4 to 8), but in either case there is no difficulty in recognizing the types. Here, as with the male smegma, the use of the dark-field microscope is important in order to avoid confusion of the organisms belonging to the *Leptospira* group with those normally present.

Examination of the spirochetal flora of female children up to the age of 2 years showed that the varieties present are similar to those found in the adult, differing from the latter only in being less numerous.

CONCLUSION.

The spirochetal flora of normal female genitalia is similar to that of the male and consists of *Treponema calligyrum*, *Treponema minutum*, and *Spirocheta refringens*. The types are present in varying proportions, but the *calligyrum* usually predominates, and the *refringens* is the least frequent. The female genitalia are much richer generally in the number of spirochetes than the male.

EXPLANATION OF PLATE 57.

Magnification, $\times 1,000$.

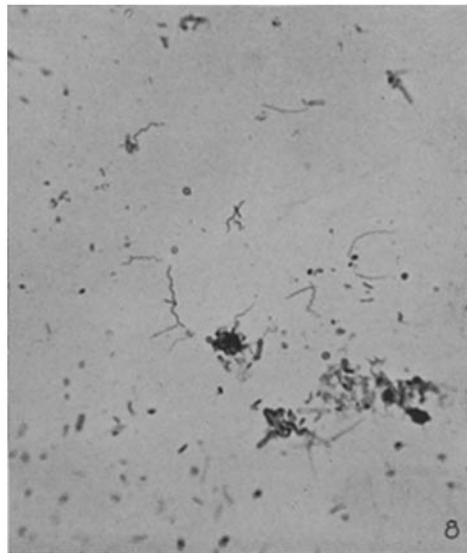
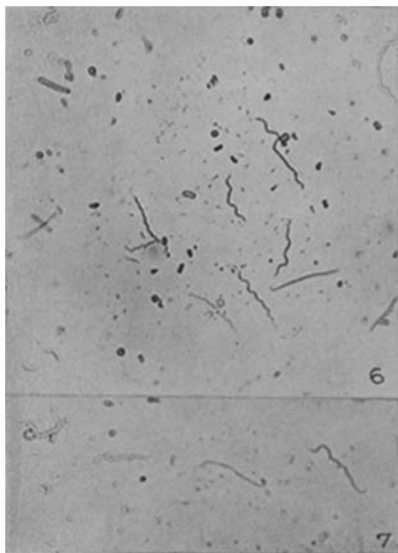
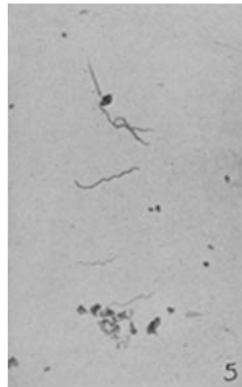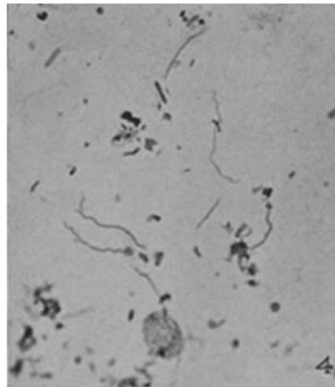
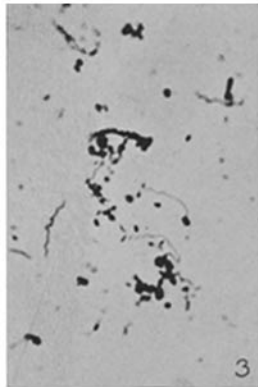
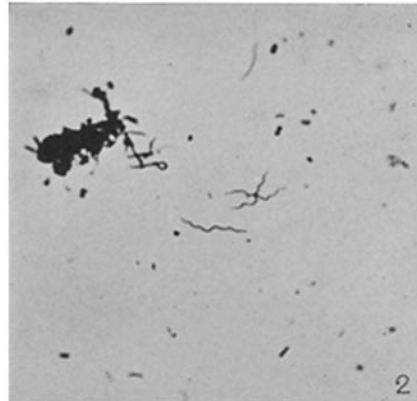
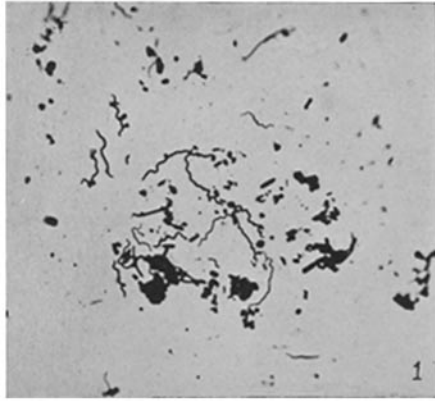
FIGS. 1 to 3. Films from female smegmas, showing *Treponema calligyrum* and *Treponema minutum*.

FIG. 4. Several specimens of *Treponema calligyrum* and a few of *Spirocheta refringens*.

FIG. 5. Several specimens of *Treponema calligyrum* and one of *Treponema minutum*.

FIG. 6. The three types.

FIGS. 7 and 8. *Treponema calligyrum* and *Treponema minutum*.



(Noguchi and Kaliski: Spirochetal flora of normal female genitalia.)