

野口英世著 Journal of Experimental Medicine 所収論文

この PDF は Journal of Experimental Medicine に掲載された論文を Rockefeller University Press の許可 (2020 年 3 月 18 日付) を得てアップロードしています。

ETIOLOGY OF YELLOW FEVER.

II. TRANSMISSION EXPERIMENTS ON YELLOW FEVER.

By HIDEYO NOGUCHI, M.D.

(From the Laboratories of The Rockefeller Institute for Medical Research.)

PLATE 35.

(Received for publication, March 27, 1919.)

For the purpose of transmitting yellow fever to animals experiments were made to reproduce the disease in whatever kind of animal was available by inoculation with the blood from patients admitted to the Yellow Fever Hospital in Guayaquil during my stay there. The blood was drawn from the median basilic vein of the patient at various stages of the disease, mainly during the 1st week, with a sterile Luer syringe and injected before coagulation into the peritoneal cavity (in mammals) or into the pectoral muscles (in birds). 10 cc. of blood were usually taken and distributed among from one to four animals in each instance. When more than one kind of animal was used for one patient correspondingly larger quantities of blood had to be drawn. The following animals were employed: ringtail monkey, rabbit, guinea pig, cat, dog, donkey, guatusa,¹ comadreja,² and ozo-melero³ among the mammals; pigeon, paloma de tierra,⁴ bluebird, mantas,⁵ blackbird, parrakeet,⁶ reedbird, blancos,⁷ and diostede⁸ among the birds.

¹ *Dasyprocta aguti* (animal akin to rabbit).

² *Bassaris bassaricyon* (?) (resembling an opossum).

³ *Cholopus didactylus* (two-toed sloth).

⁴ Family of Peristerinæ (ground-dove).

⁵ Siskin (probably).

⁶ Family of Bolborhynchus.

⁷ Similar to a magpie, but white.

⁸ Genus *Pteroglossus*.

All the animals inoculated were kept under observation at least 1 month before being discarded as negative, even when no symptoms were observed. An animal which showed a rise of temperature after a period of several days was closely watched, and when more than one of the animals of the series receiving the same blood became febrile one was killed for examination and further passage made in the same species of animal. As will be seen later (Case 2) such a step was essential with some specimens of yellow fever material, as by this means alone was it possible to reproduce an experimental condition resembling yellow fever on the third animal passage.

None of the birds showed any definite symptoms when first inoculated with the blood of yellow fever patients, but upon subsequent injection of the organ emulsion of a guinea pig with the experimental yellow fever⁹ parrakeets, mantas, blackbirds, reedbirds, and paloma de tierras died within 24 to 72 hours. There were no lesions except for hyperemia of the visceral organs. The pigeons, bluebirds, and toucans showed no definite reaction. This rather rapid death following the second inoculation may have been due to an anaphylactic phenomenon. Rabbits and guatusas showed a temperature of 40–41°C. on the 4th to 5th day after inoculation but became normal after 48 hours. There were no other symptoms, and the animals remained well during the period of observation (1 month). The ringtail monkeys showed a similar but more prolonged fever reaction lasting several days. The animals appeared depressed after 48 hours and refused to take food. The conjunctivæ were injected for several days, but there was no jaundice. Unfortunately the number of experiments with this animal was limited to five because of the difficulty in securing them in sufficient numbers. Donkeys showed no reaction to the injection of yellow fever blood in large quantities.

Apparently none of the animals enumerated above possesses a sufficient degree of susceptibility to enable the yellow fever virus to multiply and reproduce the symptoms and lesions known as yellow fever in man. It is possible that some of them had an extremely mild or atypical form of the infection.

⁹ For the sake of brevity the condition induced by inoculation will be termed "experimental yellow fever." Further evidence bearing on the validity of this term will be presented in successive papers of the series.

Since guinea pigs could be secured more easily, and in view of the success of Inada and Ido¹⁰ with this species in the study of infectious jaundice, they were extensively used during the present study. Guinea pigs are native to Ecuador and are found wild in the mountainous regions.¹¹ All except 60 of the guinea pigs which were used in these experiments (which were taken from New York) were reared in the mountains and shipped to the Yellow Fever Hospital. They stand captivity well for several months.

Experiments with Guinea Pigs.

Blood and Organ Emulsions.—Of 74 guinea pigs inoculated with the specimens of blood from 27 cases of yellow fever, 8, representing 6 cases, came down with the symptoms resembling human yellow fever. In one instance, however, the reproduction of the disease required three successive inoculations in guinea pigs. In this instance one of the animals showed a rise of temperature on the 5th day and was killed for examination and transfer on the 6th day. The liver was degenerated, and the kidneys were highly congested. A few hemorrhagic spots were found in the lungs. In a further passage of the organs to two new guinea pigs there was a similar febrile reaction with ecchymoses in the lungs but only a trace of icterus. On transfer of the second passage material typical hemorrhages, icterus, and albuminuria were induced. With the materials from only one of several autopsies was a positive transmission obtained. The details of the transmission experiments follow.

The first positive transmission was obtained in the case of Patient A.

Case 1 (Text-Fig. 1, a).—A. A., female, age 17 years; servant, native of Latacunga (9,055 feet above sea level). Had come to Guayaquil 3 months previously.

Onset, July 14, 1918. Headache, chills, fever, and severe pains throughout the body. July 15. Vomited chocolate-colored matter and felt pains in epi-

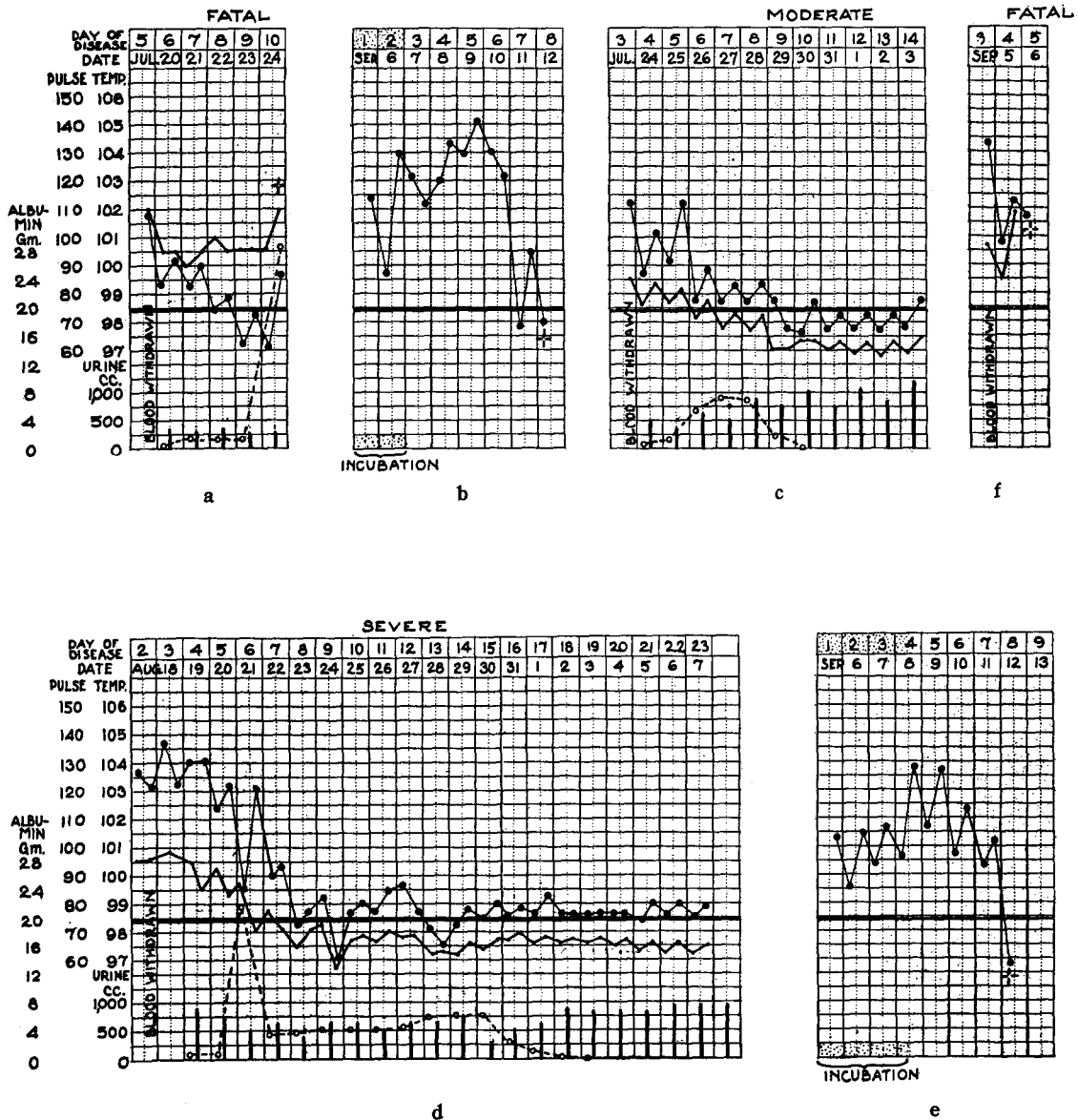
¹⁰ Inada, R., Ido, Y., Hoki, R., Kaneko, R., and Ito, H., *J. Exp. Med.*, 1916, xxiii, 377.

¹¹ Guinea pigs are in the market for food in Ecuador, but the municipality of Guayaquil has forbidden their being kept in the city on account of the possibility of spreading bubonic plague.

gastric region. July 19. Admitted to hospital. Was very sick and vomited dark bloody matter. Conjunctivæ intensely injected and distinctly jaundiced. Liver tender but not palpable. General jaundice of the skin. Blood drawn from median basilic vein into citrate solution and inoculated into guinea pigs immediately and also after 3 days cultivation at 25°C. July 20. Patient felt better, but gums began to bleed. Abdominal pains not marked. July 22. Condition worse. Patient very ill, vomited constantly ("coffee-grounds vomitus"). Jaundice very marked. Liver tender and swollen. Tumefaction of thighs because of menstruation. July 23. Delirium and insomnia with intense epigastric pains. July 24, 9 p.m. Died.

Autopsy.—Performed 11 hours post mortem. Well nourished young woman, with well marked rigor mortis and lividity. Body cyanotic and mottled. Pronounced general jaundice. Mouth and nostrils contained dark, partly dried blood clots, and face was badly smeared with dried blood. Similar blood specks were found on the hands and the genital regions, the skin of the thighs being extensively excoriated owing to hemorrhages from the uterus. No petechiæ or subcutaneous ecchymoses present. Lungs edematous. Pronounced hypostatic congestion of the dependent parts. Several ecchymoses of pea size present. Pleura free, containing moderate amount of deeply jaundiced clear fluid. On section the hemorrhagic spots of the lungs were seen to extend many centimeters into the parenchyma; some occult foci of similar ecchymoses in the interior. Some old and some new foci of tuberculosis in the upper lobes. Pericardium apparently free from any changes; scanty icteric fluid in the cavity. Heart normal in size; in diastolic state, containing fluid blood in right heart. Few minute ecchymoses on the surface. Muscles pale, flabby, and brittle. Endocardium and valves normal except for a few petechial hemorrhages on the papillary muscles. Liver pale ocher-yellow in color, fatty, and streaked with congested areas. Color on section uniformly yellow; parenchyma friable. Stomach distended with gas, containing blackish bloody mucous material; mucosa hyperemic, especially a few minute hemorrhagic spots near the cardia. Intestines filled with dark tarry contents; mucosa hyperemic. Kidneys swollen and hyperemic, capsules non-adherent; on section numerous ecchymoses in the pelvis; increase of the cortical layer and cloudy swelling. Deeply jaundiced. Suprarenal glands hyperemic. Spleen and pancreas apparently normal. Ovaries congested and uterus hyperemic, containing extravasated blood in the cavity. Small amount of deeply yellowish urine in bladder.

Animal Inoculation.—The blood, drawn on the 5th day of disease, was used in two different ways. One portion was immediately inoculated into the peritoneal cavity of two guinea pigs, and the other was put into a mixture of Ringer solution 3 parts and human serum 1 part with 0.3 per cent neutral agar, then well mixed and covered with a layer of paraffin oil. This semisolid mixture was placed in a thermostat at room temperature for 3 days (20–25°C.) and then injected into two guinea pigs intraperitoneally. The amounts of the original blood injected into each guinea pig were from 2 to 3 cc. The protocols follow.



TEXT-FIG. 1, a to f. Cases of yellow fever in which positive transmissions to guinea pigs were obtained. (a) Case 1. Age 17 years. (b) Guinea Pig 129 A. Strain, Case 1. (c) Case 2. Age 23 years. (d) Case 3. Age 20 years. (e) Guinea Pig 353 C. Strain, Case 3. (f) Case 4. Age 15 years.

Guinea Pig 50.—July 19, 1918. Inoculated with 3 cc. of the fresh blood intraperitoneally. The temperature rose to 39.6°C. on the 6th day, dropped to 38.5° on the 7th, again rose to 39.8° on the 8th, was 40° on the 9th, and 39.7° on the 10th day. The animal became less active, and on the 11th day it had a temperature of 39.1°, which continued for 3 days and then returned to normal (38–38.5°). On the 11th day the scleras appeared icteric, and the capillaries of the conjunctiva much suffused. The animal recovered completely in 15 days. On a subsequent injection (Aug. 10, 1918) with material taken from other guinea pigs inoculated with the enriched blood of the same patient this animal failed entirely to react.

Guinea Pig 51.—July 19, 1918. Inoculated intraperitoneally with 2 cc. of the same lot of blood. The temperature was 39.9°C. on the 9th day, 40.5° on the 10th, and 39.2° on the 11th, returning gradually to normal (38.5–39°). There was a suspicion of jaundice on the scleras on the 12th day which disappeared in a few days. This animal remained well and was subsequently (Aug. 10, 1918) tested against material taken from this case. It failed to react.

Guinea Pig 80.—July 22, 1918. 4 cc. of the mixture of the citrate blood and the culture medium, which had been incubated for 3 days, were injected intraperitoneally into the guinea pig. The temperature was 40°C. on the 5th day, 40.1° on the 6th, and 38° on the 7th, when the animal became distinctly jaundiced. Death occurred the same day (July 29).

Autopsy.—Marked general jaundice. No definite subcutaneous ecchymoses. Dried blood specks around the nostrils. Mucous membranes very yellow. Lungs congested; showed few disseminated ecchymotic spots which on section were seen to extend deeper into the parenchyma. The size varied from a minute point to that of a split pea, and the color from bright red to dark bluish red. The contour of these areas was usually sharply demarcated from the normal tissue. Lungs edematous and the lower lobes highly hypostatic. Pleuræ not affected. Right heart appeared dilated and contained semicoagulated cyanotic blood. A few punctiform hemorrhages on the anterior surface. Muscles friable. Liver yellowish brown in color and mottled with areas of congestion. The markings of the lobules were prominent. Consistency firmer and less succulent than the normal. Stomach distended with undigested food partly tinted with the dark blood which escaped from the hemorrhagic spots on the highly congested mucosa, especially marked near the cardia. Intestines highly hyperemic and showed numerous spots of hemorrhage along the mucosa. Contents bloody. Kidneys intensely hyperemic and more or less swollen, showing a few punctiform hemorrhages in the cortex. On section the pelvis was filled with blood and there were some ecchymoses. The cortex was broad and red, and the medulla succulent and cloudy. Adrenals hyperemic and swollen. Spleen, pancreas, bladder, and testes apparently unaffected. Along the abdominal wall the muscles were congested and showed some disseminated ecchymoses.

Microscopic Examination.—The blood was apparently free from any microorganism when examined under the dark-field microscope. Emulsions were

prepared from the liver, kidney, and adrenals for examination by dark-field and also for further passage. A very few actively motile organisms belonging to the genus *Leptospira* were demonstrated in the liver and kidney emulsions but not in the adrenal.

Passage.—Two guinea pigs were immediately inoculated with a mixture of the emulsions of the liver and kidney from Guinea Pig 80 and a further generation of this strain was obtained in the two following guinea pigs.

Guinea Pig 80 A.—July 29, 1918. The organ emulsion (2 cc.) was inoculated intraperitoneally. The animal showed a temperature of 41.3°C. on the 4th day, 40.6° on the 5th, and 38.7° on the 6th, when the color of the skin and mucosa became intensely icteric. Death occurred at 3 p.m. on Aug. 3 while the animal was being placed in a mosquito cage with the stegomyias.

Autopsy.—The general appearance was the same as that of Guinea Pig 80. The urine contained bile pigment, albumin, and abundant casts. The leptospira could not be demonstrated either in the blood, liver, or kidney.

Guinea Pig 80 B.—July 29, 1918. The emulsion was applied to the scarified surface of the skin. The highest temperature (morning) was 39.9°C. on the 7th day. It went down to 38.8° on the 9th day, when the animal became very yellow. The animal died on the 10th day (Aug. 7).

Autopsy.—About the same as in the foregoing experiment except for a higher degree of degeneration of the liver, which was ocher-yellow, exactly as in some human cases. No leptospiras were demonstrated by the dark-field microscope, but a further successful transfer was made.

Guinea Pig 81.—July 22, 1918. 5 cc. of the enriched blood of Patient A. were injected intraperitoneally. The temperature was 40.3°C. on the 6th day, 40° on the 7th day, 39.9° on the 8th, and 38.7° on the 9th day, when jaundice became noticeable. The animal was found dead on July 31.

Autopsy.—Lesions similar to those already described in Guinea Pig 80. The stomach was filled with a semifluid blackish gray matter (digested blood). Dark-field examination of the blood, liver, and kidney failed to demonstrate any organism. Transfers were made to six guinea pigs. The protocols are given below.

Passage.—July 31, 1918. Six guinea pigs were inoculated with the emulsions of the kidney and liver, intraperitoneally and also percutaneously after depilation.

Guinea Pig 124.—July 31, 1918. Kidney emulsion (1 cc.) intraperitoneally. The animal had a temperature of 40.1°C. on the 4th, 40.5° on the 5th, 39.6° on the 6th, and 39.9° on the 7th day. It continued to show high temperature for 14 days, but jaundice was not present at any time. It was discarded after 30 days (Aug. 30).

Guinea Pig 125.—The same material was used as in the foregoing experiment. The animal had a temperature of 40°C. on the 4th and 40.1° on the 5th day. After that it was 39.5° or less until the 11th day, when the animal became quite icteric. It collapsed while being used for infecting stegomyias in a cage (Aug. 10).

4 p.m.), and was killed for examination of blood, liver, and kidney. Considerable numbers of leptospiras were found in the blood and organs. Further transfers were made with success. A culture was obtained from the heart's blood, but within a week a fungus contamination destroyed it.

Passage. Guinea Pig 126.—July 31, 1918. The liver emulsion (1 cc.) of Guinea Pig 81 was inoculated into the peritoneal cavity. The temperature went up to 40°C. on the 5th, 6th, and 9th days; the animal showed definite jaundice on the 10th day and died on the 11th. The chief symptoms were all very marked.

Guinea Pig 127.—This was a duplicate of the foregoing experiment. The animal died of a secondary infection within 3 days.

Guinea Pig 128.—Percutaneous inoculation with a mixture of the liver and kidney emulsions of Guinea Pig 81. The animal had a temperature of 40°C. during the 10th, 11th, and 12th days, but it had normally registered as high as 39.5°. There was a trace of jaundice on the 13th day, which soon disappeared. The animal remained well for 31 days and was discarded as negative.

Guinea Pig 129.—This was a duplicate of the foregoing experiment. Temperature 40.3°C. on the 7th and 40.1° on the 8th day, when a suspicion of jaundice appeared. It was killed on the 8th day in order to ascertain the lesions and obtain material for culture and transfers.

Autopsy.—Jaundice too slight to be definitely recognized. The lungs, however, showed the beginning of ecchymotic spots, and the liver and kidneys were highly congested. Dark-field examination failed to reveal any organism. Transfers were made to two guinea pigs on the same day (Aug. 7). One of them died with mild but typical lesions, while the other completely recovered after having shown a temperature of 40° and 40.4°C. on the 7th and 8th days.

Text-fig. 1, *b* is the chart of Guinea Pig 129 A, which succumbed to the intra-peritoneal inoculation of 0.5 cc. of a culture of this strain (Aug. 27–Sept. 5, 1918), with typical symptoms and lesions. The leptospira was demonstrated in the liver.

The foregoing experiments are of great interest as they indicate that the microorganism which was responsible for the disease and subsequent death of this patient was apparently successfully transmitted to the guinea pig. The failure of the unmodified blood to reproduce the disease in guinea pigs as contrasted with successful transmission by means of the same blood after a temporary enriching of the virus *in vitro* may be explained by the fact (as subsequent experiments concerning the properties of the serum of yellow fever patients and the properties of the organism indicate) that the inoculation of the fresh blood carried with it a certain amount of antibodies antagonistic to the development in the body of the guinea pig, while this

property is certain to be considerably modified when incubated in the culture medium employed. Moreover, as the organism is capable of multiplying outside the body at room temperature there is temporary enrichment of the organisms before inoculation into the guinea pig.

It is also shown in this experiment that the microorganism is variable in virulence, being able to produce a fatal infection in some, an abortive infection in others, and in still others no infection at all. The organism is capable of entering the body of the guinea pig in some instances by the smearing of the infective material. That there is an abortive form of the infection is shown by the immunity that it confers upon the guinea pigs which survived such an infection. The infective agent may be passed from one guinea pig to another by timely transmission.

A leptospira has been found to be associated with this case, but its demonstration by means of the dark-field microscope is not always successful; it may or may not appear in a subsequent passage. That this organism, notwithstanding the difficulty of demonstrating it, is etiologically related to the disease known as yellow fever in Guayaquil is made highly probable by subsequent experiments.

Fig. 1 shows the organism in the blood of a guinea pig inoculated with the culture of this strain.

The second positive transmission was obtained in the case of Patient P.

Case 2 (Text-Fig. 1, c).—C. P., male, age 23 years; tailor, robust, a native of Cuenca (highland). Had been in Guayaquil a month.

Onset July 20, 1918. Felt fever without chills; severe headache, photophobia, muscular pains throughout body, cramps in legs. No nausea. July 23. Admitted to hospital. Marked injection of the conjunctiva; slight jaundice; much albumin in the urine. Liver small but tender (Dr. Elliott). Temperature 38.9°C. Blood was drawn from the median basilic vein and injected into two guinea pigs (see protocols). July 24. Epistaxis in the morning. July 25. Nauseated easily; diarrhea. Little urine since yesterday. July 26. Jaundice advanced. Albuminuria + + +. July 31. Improving. Temperature normal. Aug. 2. Trace of jaundice. No albumin in the urine. Aug. 3. Discharged.

Animal Inoculation. Guinea Pig 88.—July 23, 1918. Intraperitoneal injection of 4 cc. of the blood of Patient P. (4th day of disease). Temperature rose to 39°C. on the 4th and 40° on the 5th day. The animal was killed on the 6th day for further passages into two guinea pigs.

Autopsy.—Lungs showed a few hemorrhagic spots. Liver congested and somewhat yellowish (fatty). Kidneys congested and cloudy, showing swelling on section. Gastrointestinal system hyperemic but showing no hemorrhages. Spleen normal.

First Passage. Guinea Pig 88 A.—July 28, 1918. Received 1 cc. of blood of Guinea Pig 88 intraperitoneally. The temperature rose to 39.9°C. on the 7th day; killed on the 10th day for examination and transfer.

Autopsy.—Slight icterus. The lungs were spotted with a few ecchymoses. Liver congested and perhaps fatty. Kidneys congested and showed cloudy swelling on section. Intestine hyperemic and showed scattered hemorrhagic foci.

The liver and kidneys were emulsified and used for inoculating two normal guinea pigs (see second passage). *Leptospiras* not found.

Guinea Pig 88 B.—Duplicate of No. 88 A. This animal showed a slight rise of temperature in 4 days, but during observation for further evolution of the reaction it became normal and was discarded on Aug. 22.

Second Passage. Guinea Pig 89 A.—Aug. 6, 1918. 1 cc. of the mixed emulsion of the liver and kidney of Guinea Pig 88 A was given intraperitoneally. The temperature went up to 40.9°C. on the 3rd, 39.6° on the 4th, and 40° on the 5th day, but fell to 38.6° on the 6th day. Epistaxis and icterus. The animal was found dead on the 7th day.

Autopsy.—Extremely jaundiced. Lungs hemorrhagic; liver yellowish; kidneys congested, with some ecchymoses. Stomach and intestines contained blackish matter and numerous hemorrhagic areas were present on the mucosa. *Leptospiras* were demonstrated in the liver and kidney but not in the blood. Transfers to two normal guinea pigs were made, but this strain was lost because of intercurrent infection.

Guinea Pig 89 B.—Duplicate of No. 89 A. This animal showed less fever than usual in the 1st week but 40°C. on the 10th day. It was kept under observation until Aug. 22, but nothing further developed.

Guinea Pig 89.—This was one of the two guinea pigs inoculated with the blood of Patient P. on July 23. This animal showed a temperature of 39.3°C. on the 4th, 39.9° on the 5th, 39.2° on the 6th, 38.9° on the 7th, 39.4° on the 8th, and 39° on the 9th day. It was found dead on the 10th day.

Autopsy.—Congestion of the lungs, liver, and kidneys, but no icterus. No transfer was made.

The third positive transmission was obtained with the blood of Patient G.

Case 3 (Text-Fig. 1, d).—M. G., male, age 20 years; servant, robust, a native of Ambato (8,435 feet above sea level); had been in Guayaquil 2 months.

Onset Aug. 16, 1918, 10 a.m. General pain and aching; headache; fever without rigor; no nausea, vomiting, or bleeding. Aug. 17. Admitted to hospital. Eyes injected, face flushed; much prostrated. Pains in the head and limbs were

intense. Albuminuria slight; no casts. Temperature 39.9°C. Blood taken for transmission experiments. Aug. 18. Albuminuria increasing; temperature 40.3°. Condition worse. Total leucocytes 9,200 (Dr. Elliott). Aug. 19. Albuminuria increasing and numerous casts in the urine. Temperature still 40°C. Aug. 21. Delirious; otherwise condition the same. Aug. 22. No urine obtained; gums bleeding; jaundice definite; remission in fever. Aug. 23. Decided improvement; temperature going down. Aug. 26. Beginning hematuria; increased icterus. Aug. 29. Continued hematuria; great prostration. Aug. 30. Hematuria diminished; general improvement. Sept. 1. Continued improvement; cessation of hematuria. Sept. 2. Continued improvement; intense jaundice. Sept. 3. Slight pain in bladder. Sept. 7. Discharged.

Animal Inoculation. Guinea Pig 351.—Aug. 17, 1918. 3 cc. of the blood of Patient G. (2nd day of disease) were given intraperitoneally. The animal was kept under observation until Sept. 7 but remained without any noticeable reaction except that its temperature rose to 40.1°C. on the 18th day. Discarded as negative.

Guinea Pig 352.—Aug. 17, 1918. 5 cc. of the same specimen of blood were given. Temperature 40°C. on the 7th day, 39.8° on the 8th, and 39.6° on the 9th, but later returned to normal (38.6° for this animal). Tested for immunity on Sept. 7 against the A. strain and found to be resistant.

Guinea Pig 353.—Aug. 17, 1918. 6 cc. of the blood from Patient G. were inoculated intraperitoneally. The temperature rose to 40°C. on the 7th and 39.6° on the 8th day, but dropped to 38° on the 9th day. The animal was markedly icteric and was killed for examination of the blood and organs as well as for transfer and cultivation of the virus.

Autopsy.—The lungs showed a moderate number of ecchymoses. Liver light yellowish brown in color. Kidneys showed acute parenchymatous nephritis; no ecchymoses. Stomach contained a few hemorrhagic foci near the cardia with blood-stained contents. Intestines hyperemic but with few hemorrhages. Intense jaundice everywhere. Spleen normal in appearance. After a long search a few leptospiras were discovered, but the number was so extremely small that preliminary examination revealed none. Transfers were made successfully to two normal guinea pigs, and cultures were also obtained. The organism was demonstrated in the blood of guinea pigs inoculated in later experiments with this strain (Fig. 2).

First Passage. Guinea Pig 353 A.—Aug. 26, 1918. Inoculated with 1 cc. of the blood of Guinea Pig 353. Except for a slight rise in temperature nothing happened during the period of observation (up to Sept. 10).

Guinea Pig 353 B.—Duplicate of the foregoing experiment. This animal came down with typical symptoms and lesions on Sept. 5, 1918; that is, on the 10th day after the transfer.

Second Passage. Guinea Pig 353 C.—Sept. 5, 1918. Inoculated with the emulsion of liver of Guinea Pig 353 B. The course of the infection was similar to that of the positive instance, with the temperature as shown in Text-fig. 1, e.

The fourth positive transmission was obtained with the blood of Patient Co. Successful transmission was also made with the liver emulsion of this patient, as described below.

Case 4 (Text-Fig. 1, f).—J. Co., male, age 15 years; servant, native of Cuenca (highland). Had been in Guayaquil a month and a half.

Onset Sept. 2, 1918. Headache and pains in waist and legs; fever. Sept. 4. Admitted to hospital. Face flushed; conjunctiva injected and slightly jaundiced; gums reddish and swollen; tongue coated, with red tip and edge. Herpes labialis present.¹² No epigastric pain. Blood drawn for inoculation. Sept. 5. Passed no urine, but appeared calm. Increased jaundice. In the afternoon became excitable, anxious, complained occasionally of dyspnea. Melena. Sept. 6. Coma began previous night. Black vomit. Complete anuria. Death occurred at 9 a.m.

Autopsy.—A partial autopsy within 1 hour after death. Liver highly degenerated and yellow. In the emulsion a few leptospiras were found. Kidney congested, cloudy swelling. No leptospiras.

Animal Inoculation. Guinea Pig 435.—Sept. 4, 1918. Intraperitoneal injection of 3 cc. of the blood of Patient Co. (3rd day of disease). The animal showed a temperature of 39°C. on the 8th, 40° on the 9th, 39.9° on the 10th, and 39° on the 11th day, but subsequently a normal temperature. It was discarded as negative after 25 days.

Guinea Pig 436.—Duplicate of the foregoing experiment. 5 cc. of the blood injected. The temperature rose to 39.9°C. on the 9th and 40.1° on the 10th day, coming down to 38.2° on the 12th day. The animal showed distinct icterus on the 11th and 12th days and died during the night of the latter.

Autopsy.—General jaundice. Hemorrhages in the lungs and gastrointestinal tract. Liver brownish yellow. Kidney highly congested; showed cloudy swelling on section. Other organs normal in appearance. Leptospira found under the dark-field microscope and in stained slides (Fig. 3).

The fifth positive transmission was obtained with the emulsion of the liver of the same patient, who died on the 5th day. The material was taken from the body within 1 hour, and the emulsion made with Ringer's solution was inoculated intraperitoneally into four guinea pigs, the quantity for each being 1 cc. A few distorted immobile leptospiras were demonstrated in this emulsion under the dark-field microscope.

Guinea Pigs 444 and 446.—Sept. 6, 1918. Received 1 cc. of the liver emulsion from Patient Co. Died on the night of the following day.

¹² See Fig. 3, Paper I.

Guinea Pig 447.—Duplicate of the foregoing experiment. This animal never showed a reaction and died from an intercurrent infection after 22 days.

Guinea Pig 445.—Duplicate of the foregoing experiment. The animal had a temperature slightly above 39°C. for 6 days which rose to 39.9° on Sept. 13 and to 39.7° on the following day. Sept. 15. The animal was distinctly icteric and was killed for examination and transfer.

Autopsy.—Typical lesions in the lungs, stomach, liver, and kidneys. The blood, as well as the liver and kidney, showed a few leptospiras.

Passage.—From this animal the strain has been successfully passed through many generations. A culture also was obtained from a later passage.

The sixth positive transmission was obtained with the blood of Patient Ch., drawn from the median basilic vein on the 5th day of the disease and 48 hours previous to his death. In this instance 2 cc. of the fresh blood were directly inoculated into the peritoneal cavity of each of the two guinea pigs.

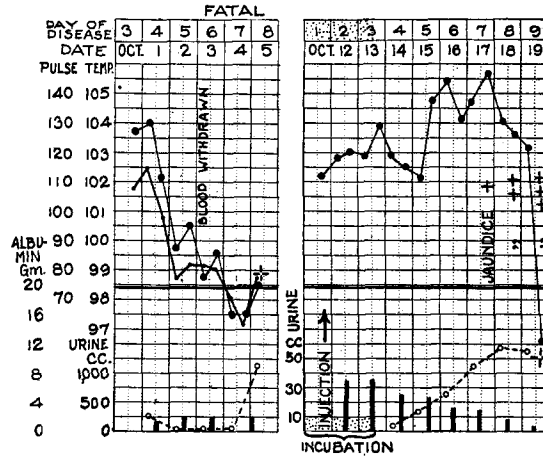
Case 5 (Text-Fig. 2, a).—E. Ch., male, age 30 years; well built man, a native of Guamote (highland). Had lived in Guayaquil for 8 months.

Onset Sept. 28, 1918. Sudden fever with chills, headache, pains in the limbs and back. Admitted to hospital on Sept. 30. Still complained of pains in the body and headache, with injection of the conjunctivæ; tongue coated, with free edge and tip; gums swollen. Albumin and casts in the urine, which was diminished in volume. Oct. 1. Scleras and skin somewhat yellowish. Oct. 2. All symptoms aggravated. Oct. 3. Chest showed several pea-sized hemorrhagic spots, slightly raised. Extensive ecchymotic areas were found on the skin where the patient had applied mustard.¹³ Jaundice marked; gums bleeding. Frequent emission of black vomit. The blood was transmitted to guinea pigs at 2.30 p.m., Oct. 4; condition becoming worse; anuria. Oct. 5, 3 p.m. Died.

Autopsy.—Performed 2 hours after death. Intense jaundice throughout the entire body. Skin over the chest showed numerous dark hemorrhagic spots. Lungs much congested, showing many hemorrhagic spots. Liver bright yellowish in color, friable, and fatty. Kidneys highly congested, with cloudy swelling; some small ecchymotic foci in the pelvis. Capsules not adherent. Stomach and intestines hyperemic with blackish bloody contents. Heart showed a few ecchymoses in the pericardium and endocardium; muscles degenerated. Bladder contracted with small amount of dark yellow urine. Spleen, pancreas, suprarenal glands, and testes apparently unchanged.

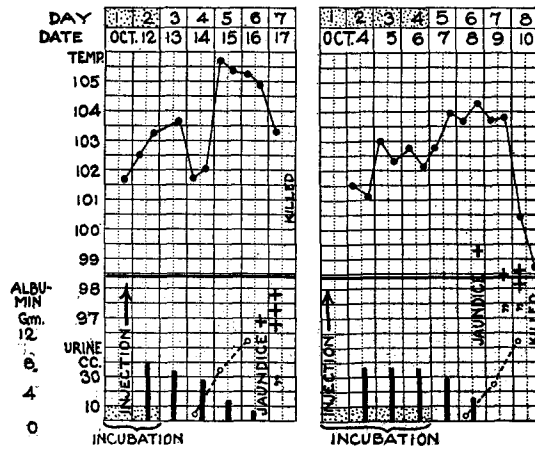
Animal Inoculation. Guinea Pig 790 (Text-Fig. 2, d).—Oct. 3, 1918, 2.32 p.m. Injected intraperitoneally with 3 cc. of blood from Patient Ch., on the 6th day of disease. Temperature rose to 40.2°C. on the 6th and 39.8° on the 7th day

¹³ See Fig. 1, Paper I.



a

b



c

d

TEXT-FIG. 2, a to d. Direct transmissions from patient to guinea pig by means of injection of the blood of Patient Ch., Case 5. (a) Case 5. Age 30 years. (b) Guinea Pig 790 B. Strain, Case 5. (c) Guinea Pig 790 A. Strain, Case 5. (d) Guinea Pig 790. Strain, Case 5.

and came down to 37° on the 8th day, when the scleras and skin were intensely jaundiced. The animal was rapidly weakening and was killed for examination of the lesions and also for cultivation of material.

Autopsy.—Epistaxis; hemorrhagic lesions in the lungs and gastrointestinal tract. Liver pale yellow and fatty, and kidneys and suprarenal glands congested and swollen. Other organs apparently unchanged. In the blood and emulsions of the liver and kidneys the leptospiras were demonstrated. A pure culture was obtained from the blood of this animal.

Guinea Pig 791.—Duplicate of the foregoing experiment. The animal did not become infected.

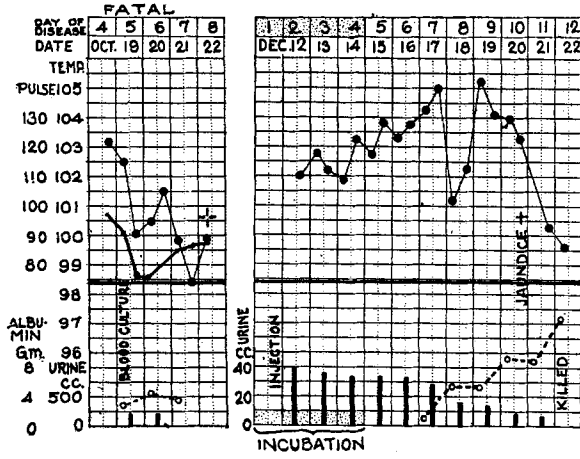
Passage.—Two guinea pigs were inoculated intraperitoneally on Oct. 11 with 1 cc. of blood from Guinea Pig 790, and both came down with typical symptoms and lesions within 8 days (Text-fig. 2, *b* and *c*). The leptospiras were demonstrated in the blood and emulsions of the liver and kidneys. Pure cultures were obtained from the blood of these guinea pigs.

The seventh positive transmission was obtained with a culture derived directly from the blood of Patient A. Ce.

Case 6 (Text-Fig. 3, a).—A. Ce., female, age 18 years; seamstress, from a coast town of Vinces. Had been in Guayaquil 12 days.

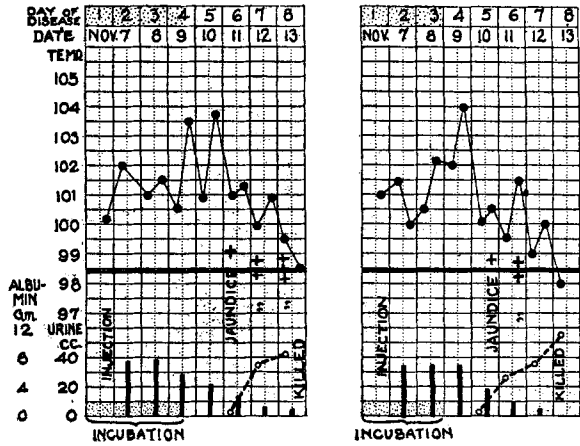
Onset with chills and fever on Oct. 16, 1918, followed by headache, pains in the back, legs, and epigastric region. Vomited yellowish matter. Admitted on Oct. 18. Slight jaundice; marked albuminuria; intense pain throughout the body; nausea. Several petechial hemorrhages on the chest and arms. Oct. 19. Jaundice more distinct; tongue coated, with free edge and tip; bilious vomit; albuminuria; oliguria. Patient gravely ill. Blood culture made. Oct. 20. All symptoms becoming worse. Black vomit and profuse bleeding from the gums. Oct. 21. Comatose all day. Oct. 22, 8 a.m. Died. Autopsy not performed.

The culture tubes were examined on October 26, 1918, 7 days after they were set up, by the dark-field microscope. Only one of the six tubes showed the presence of active leptospiras in small numbers. From this twelve subcultures were made. The other tubes remained apparently without growth. Inoculations into guinea pigs were made at three different laboratories, first in the laboratory of the Yellow Fever Hospital in Guayaquil on October 27, then in the laboratory of the Colon Hospital, Panama Canal, on November 7, and finally in the laboratory of The Rockefeller Institute on December 11 and 19; that is, 8, 17, 44, and 52 days respectively after the time of making the cultures. Subsequent subcultures



a

b



c

d

TEXT-FIG. 3, a to d. Indirect transmission from patient to guinea pig by means of culture derived from the blood of Patient Ce., Case 6. (a) Case 6. Age 18 years. (b) Guinea pig. Strain, Case 6. Second passage from culture. (c) Guinea pig. Strain, Case 6. Culture 2. (d) Guinea pig. Strain, Case 6. Culture 3.

of this strain have since been obtained (Figs. 5 and 6). The protocols of some of these series of inoculations of guinea pigs with the cultures follow.

Animal Inoculation (Second Series). Guinea Pig CeI₂ (Text-Fig. 3, c).—Nov. 7, 1918. Inoculated intraperitoneally with 0.5 cc. of the culture (17 days old) of blood from Patient Ce. Temperature 39.8°C. on the 4th day, 40° on the 5th, 39° on the 6th, and 37.2° on the 7th. Suffusion of the conjunctivæ, ears, and soles. Slight jaundice appeared on the scleras, ears, and skin on the 7th day. The urine contained bile pigment and albumin. The animal was killed on Nov. 13 for examination and culture.

Autopsy.—Moderate general jaundice. Many spots of hemorrhage in lungs; liver congested and brownish dark red; kidneys swollen and cloudy; gastrointestinal mucosa hyperemic and somewhat hemorrhagic; spleen not altered.

Guinea Pig CeI₃ (Text-Fig. 3, d).—The same as the foregoing experiment. The animal showed symptoms and lesions almost identical with those just described.

Animal Inoculation (Third Series). Guinea Pig 4, Second Passage from No. CeI₂ (Text-Fig. 3, b).—Dec. 11, 1918. Inoculated intraperitoneally with 0.5 cc. of the liver emulsion of guinea pig infected with the first generation of culture of Ce. strain (35 days old) which had never been passed through any animal. Temperature 39.5°C. on the 4th, 39.8° on the 5th, 40.6° on the 6th, 38.8° on the 7th, 41° on the 8th, 40° on the 9th, 38° on the 10th, and 37.6° on the 11th day. The animal became intensely yellow throughout the entire body and was killed for culture and examination.

Autopsy.—All tissues were deeply jaundiced, and there were some minute ecchymoses in the subcutaneous and muscular tissues. The lungs showed large and small irregular hemorrhagic spots which on section were seen to extend into the parenchyma. The color of the liver was strikingly yellow. Kidneys swollen and on section cloudy; marking indistinct. Substance of kidney deeply jaundiced. Suprarenal glands congested. Mucosa of the gastrointestinal tract hyperemic. Some hemorrhages, staining the contents blackish red. Spleen not visibly affected. Only a few leptospiras found in the kidneys and none in the blood or liver.

In addition to the animals given above five more guinea pigs were inoculated in the same series. All showed symptoms and lesions similar to those just outlined. Fig. 4 shows the organism in a stained blood preparation from one of the infected guinea pigs.

The instance just described confirms the results obtained in the first positive transmission experiment (Case A.); namely, that the leptospira can be directly cultivated from the blood of yellow fever patients and then inoculated into guinea pigs with reproduction of

the symptoms and lesions which characterize the disease in man. As we shall note again elsewhere, the virulence of this organism was maintained in cultivation for more than 5 weeks.

To sum up the results recorded in the preceding series of experiments, it is shown that there exists in certain cases of yellow fever prevalent in Guayaquil a definite organism which is capable of being transmitted to the guinea pig and reproduces the symptom complex characteristic of yellow fever. As other experiments showed, the organism which has been observed and isolated in Guayaquil is a leptospira (Figs. 1 to 6) closely resembling the *Leptospira icterohæmorrhagiæ* of Inada and Ido,¹⁰ discovered by them in the infectious jaundice of temperate climates. That the present organism is closely allied to but immunologically distinct from that species of the infectious jaundice has since been established and the experiments bearing on this point will be discussed in detail in subsequent papers. For the present I shall refer to the organism isolated from the yellow fever (typhus icteroides) cases as the yellow fever leptospira, or *Leptospira icteroides* (ἰκτερος, jaundice, + εἶδης, resembling, like), thus denoting the source from which it was obtained.

Negative and Abortive Infections.

In the twenty-one instances to be recorded there was either a temporary febrile reaction in the guinea pigs after inoculation of the blood, with or without any suspicion of jaundice, or almost no reaction at all. In other words, the results are classed as indefinite or negative. It is noteworthy, however, that a considerable proportion of the guinea pigs inoculated with the blood drawn during the first 5 days of the disease had a febrile reaction either on the 4th, 5th, 6th, or 7th day, and in some of these animals even a trace of jaundice was noted or suspected for a day or two soon after the fever. In none did the jaundice become definite, and the animals subsequently returned to normal. Undoubtedly, by transferring the virus to normal animals at this stage more strains might have been secured in passage, but much time was lost in watching further development of the symptoms, and opportunities to obtain the strains were lost. Some of these animals must have had a mild or abortive

TABLE I.

| Case No. | Sex. | Age. yrs. | Course of disease. | Day of disease on which blood was taken. | No. of guinea pigs inoculated. | Outcome of inoculation. |
|----------|---------|--------------|-----------------------------|--|--------------------------------|--|
| 7 | Male. | 21 | Severe; recovery. | 2nd | 2 | Febrile reaction only. |
| 8 | " | 21 | " " | 2nd | 2 | " " in one, fever and trace of icterus in other; recovery in both. |
| 9 | " | 19 | Moderate; " | 2nd | 2 | No reaction in one, fever and trace of icterus in other; recovery in both. |
| 10 | Female. | 26 | Severe; died on 7th day. | 2nd | 2 | No reaction. |
| 11 | " | 10 | Extremely mild. | 2nd | 2 | " " in one, slight fever in other. |
| 12 | " | 40 | Moderate; recovery. | 2nd | 2 | Febrile reaction in both. |
| 13 | Male. | 35 | Mild; " | 3rd | 2 | " " " " |
| 14 | " | 23 | Severe; " | 3rd | 2 | No reaction in one, fever in other. |
| 15 | " | 25 | Very mild; " | 3rd | 2 | Fever in both. |
| 16 | " | 25 | Moderate; " | 3rd | 2 | " " " and suspicion of icterus; both recovered. |
| 17 | " | 19 | Severe; died on 6th day. | 3rd | 1 | Fever and suspected trace of icterus; recovered. |
| 18 | " | 23 | Severe; died on 7th day. | 4th | 1 | Fever and suspicious yellow tint in scleras; recovered. |
| 19 | " | 25 | Severe; recovery. | 4th | 2 | Febrile reaction in both and suspicion of icterus in one. |
| 20 | " | 20 | " " | 4th | 2 | Fever in both and perhaps a trace of icterus. |
| 21 | " | 28 | Severe; died on 4th day. | 4th | 3 | All had a febrile reaction but no icterus. |
| 22 | " | 16 | Severe; died on 10th day. | 5th | 2 | Both had fever and suspiciously yellow scleras. |
| 23 | " | 16 | Moderate; recovery. | 5th | 1 | Febrile reaction. |
| 24 | " | 20 | Severe; died in 6 (?) days. | 5th(?) | 2 | Both had fever. Suspicion of icterus in one. |
| 25 | Female. | 21 | Mild; recovery. | 6th | 2 | Fever in one, no reaction in other. |
| 26 | Male. | 21 | Severe; " | 8th | 2 | No reaction in either. |
| 27 | " | 32 | " died on 16th day. | 14th | 2 | " " " " |
| 27 | " | 32 | Severe; died on 16th day. | 15th | 2 | " " " " |

form of the infection, as they subsequently proved to be refractory to a virulent virus when tested after a period of about 25 days from the time of the inoculation of the yellow fever blood. For the sake of completeness the protocols of the negative transmission experiments are recorded in Table I.

SUMMARY.

By injecting into guinea pigs the blood of yellow fever cases occurring in Guayaquil a group of symptoms and lesions closely resembling those observed in human yellow fever were induced in a limited number of instances. Of 74 guinea pigs inoculated with specimens of blood from 27 cases of yellow fever, 8, representing 6 cases, came down with the symptoms; namely, a marked rise of temperature after a period of incubation averaging 3 to 6 days, with simultaneous suffusion of the capillaries, particularly of the conjunctivæ and soles, then preliminary hyperleucocytosis followed by progressive leucopenia, the early appearance of albumin and casts in the urine, which gradually diminishes in volume as the disease progresses. The fever lasts only a few days, rapidly dropping first to the normal and then usually to subnormal. At this period jaundice manifests itself in varying degrees of intensity, first in the scleras, then in the skin and the urine. Hemorrhages from the nasal or gingival mucosa or anus have been observed to occur during this period. Autopsies reveal deep jaundice throughout the entire tissue. The liver is fatty and yellow, the kidney hyperemic, and often swollen and hemorrhagic. Hemorrhagic spots were almost always found in the lungs and gastrointestinal mucosa. Guinea pigs are usually rather sensitive to the infection, though many appeared to be somewhat resistant and some even refractory.

The injection of the yellow fever blood into ringtail monkeys, rabbits, cats, guatusas, weasels, and sloths among the mammals, and pigeons, ground-doves, bluebirds, mantas, blackbirds, parakeets, reedbirds, blancos, and toucans among the birds, gave negative results.

In the blood, liver, and kidneys of the guinea pigs experimentally infected with the blood of yellow fever patients a minute organism

was demonstrated which closely resembles in morphology the causative agent of infectious jaundice (*Leptospira icterohæmorrhagiæ*).

The leptospira transmitted from yellow fever cases to guinea pigs was found to induce similar symptoms and lesions upon further passage into normal guinea pigs.

The leptospira obtained from cases of yellow fever has been given the provisional name of *Leptospira icteroides*.

I wish to express my thanks to Dr. León Becerra, General Director of the Department of Health of Ecuador, and his staff for their support and cooperation in the execution of this work; and likewise to Dr. Pareja of the Guayaquil Yellow Fever Hospital and to his laboratory staff (Dr. Larrea), clinical staff (Dr. Davila and Dr. Martinez), and nursing staff for their invaluable assistance.

To Dr. Herman B. Parker I am indebted for his courtesy in lending me a dark-field arc lamp during the period before my own arrived, when the dark-field work would otherwise have been impossible, and also in furnishing me on various occasions with clinical material.

I am indebted to Colonel McCormack, Chief Health Officer of the Canal Zone, to Major Teague and Captain McFarland of the Ancon Hospital, and to Captain Bowen and Lieutenant Levy of the Colon Hospital, for the facilities afforded me in making renewal of cultures and transfers of strains to new animals.

EXPLANATION OF PLATE 35.

FIG. 1. *Leptospira icteroides* in the blood of a guinea pig experimentally inoculated with culture of strain from Patient A. A., Case 1. Fixed in methyl alcohol and stained with Wright's stain. The film was made on the 6th day of illness. $\times 1,000$.

FIG. 2. The same; strain from Patient M. G., Case 3. $\times 1,000$.

FIG. 3. The same; strain from Patient Co., Case 4. $\times 1,000$.

FIG. 4. The same; strain from Patient A. Ce., Case 6. $\times 1,000$.

FIG. 5. Dark-field view of a culture 16 days old of *Leptospira icteroides*. Strain from Patient A. Ce., Case 6. $\times 1,000$.

FIG. 6. The same. $\times 1,000$.

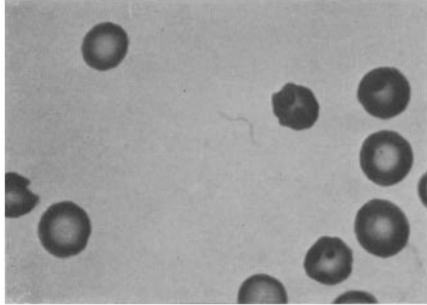


FIG. 1.

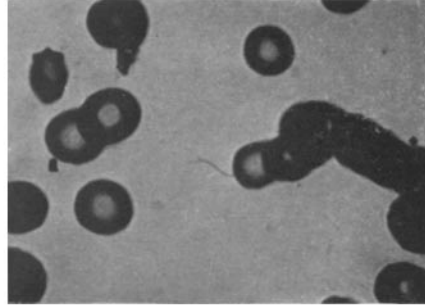


FIG. 2.

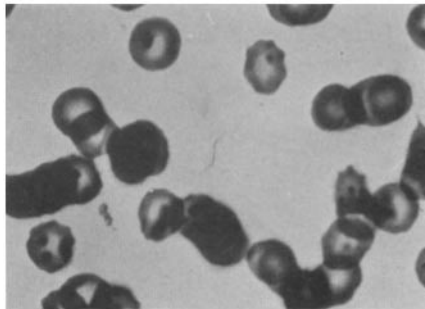


FIG. 3.

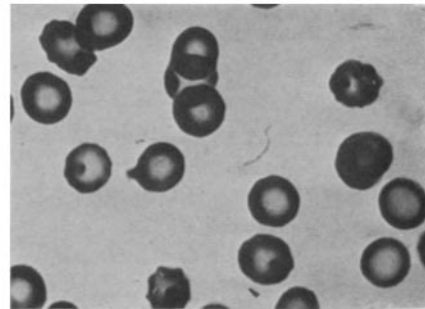


FIG. 4.




FIG. 5.

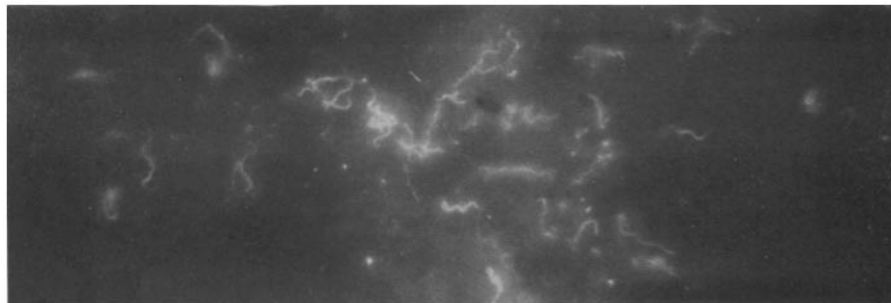


FIG. 6.

(Noguchi: Etiology of yellow fever. II.)